

CHRONIC LYMPHOCYTIC LEUKEMIA PRESENTING AS IRRITATIVE LOWER URINARY TRACT SYMPTOMS AND NON-VISIBLE HEMATURIA: AN ATYPICAL UROLOGY PRESENTATION

Muhammad Iqbal and Basharat Jameel

The Alan de Bolla Urology Department, Wrexham Maelor Hospital, Wrexham, North Wales

Corresponding author: driqbal83@hotmail.com

Submitted: June 10, 2019. Accepted: July 9, 2019. Published: July 22, 2019.

ABSTRACT

Chronic lymphocytic leukemia (CLL) is an uncommon hematological disease affecting people with recurring infection and is associated with increased risk of progression to high-risk cancer. Bladder CLL is a rare disease hence prognosis and best treatment option is not clearly understood. CLL commonly affects middle-aged women. It presents as abdominal pain, urinary difficulty, fatigue and general symptoms like fever, weight loss and loss of appetite. Chemotherapy, surgery, and radiation is the mainstay of treatment. Prognosis depends on multiple factors including subtype, stage of lymphoma, the progression of the condition, response to treatment, and overall health of the patient. The risk of recurrence and progression to other cancer is very high in bladder CLL which necessitates a strict follow-up protocol. We present a case of an 87-years-old patient presenting with persistent non-visible hematuria and storage lower urinary tract symptoms. Hematuria workup leads to the diagnosis of CLL. Hematology multi-disciplinary team recommended follow up.

Keywords: *Chronic lymphocytic leukemia, Non-visible Hematuria, Storage lower urinary tract symptoms, Chemotherapy, Multi-disciplinary team*

Chronic lymphocytic leukemia (CLL) is a rare disease, although it is the commonest type of chronic leukemia. Out of the 8600 cases of leukemia diagnosed in the UK each year, 3200 are CLL.^{1,2} The disease is commonly diagnosed in the patient over 50 years of age with increased incidence in patients between 55 and 75 years of age. The exact cause of CLL is unknown, it is thought to arise from a DNA mutation resulting in the production and proliferation of abnormal lymphocytes. Commonly CLL patients have frequent infections and diagnosis is made following an extensive investigation. A close follow up is required in view of the increased transformation to a more aggressive malignancy. Lishner et al reported 1.7 times increased risk of other cancers such as skin, lung, and gastrointestinal cancer.³ Tsimberidou et al.

reported that 11.2 % CLL patients develop second malignancies at a median of 2.9 years.⁴ We report a patient with storage Lower Urinary Tract Symptoms (LUTS) who were referred for evaluation of persistent microscopic hematuria.⁵ Cystoscopy and biopsy showed bladder CLL and further systemic evaluation revealed hematological abnormalities of CLL.

CASE REPORT

An 87-year-old gentleman was referred for the evaluation of persistent non-visible hematuria. He had storage LUTS in the form of frequency, urgency, and nocturia. There was no history of visible hematuria, urinary tract infection, abdominal pain, tiredness, or weight loss. Past medical history was significant for two TURPs. Clinical examination was unremarkable.

The patient underwent hematuria workup including flexible diagnostic cystoscopy and ultrasound KUB.

Flexible cystoscopy revealed globally distributed, multiple erythematous patches in the bladder mucosa (Figure 1). Biopsy of the erythematous lesions was done and sent for histopathological examination. The morphological and immunophenotypical features were those of CLL (Figure 2). Blood tests showed WBC count of 15400/mcL and lymphocyte count of 9600/mcL. Hb, LFTs, RFTs were normal. The lymphoproliferative disorder screening showed low forward scatter, weak kappa and a CD5+/ CD10-/ CD19+/ CD20+/ CD23+/ FMC7-/ CD79b-/ CD43+ phenotype consistent with B cell CLL. Ultrasound examination of abdomen was normal.

FIG. 1 Flexible cystoscopy revealed globally distributed, multiple erythematous patches in the bladder mucosa.

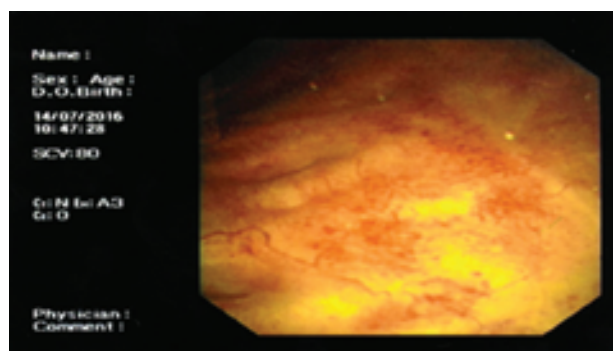
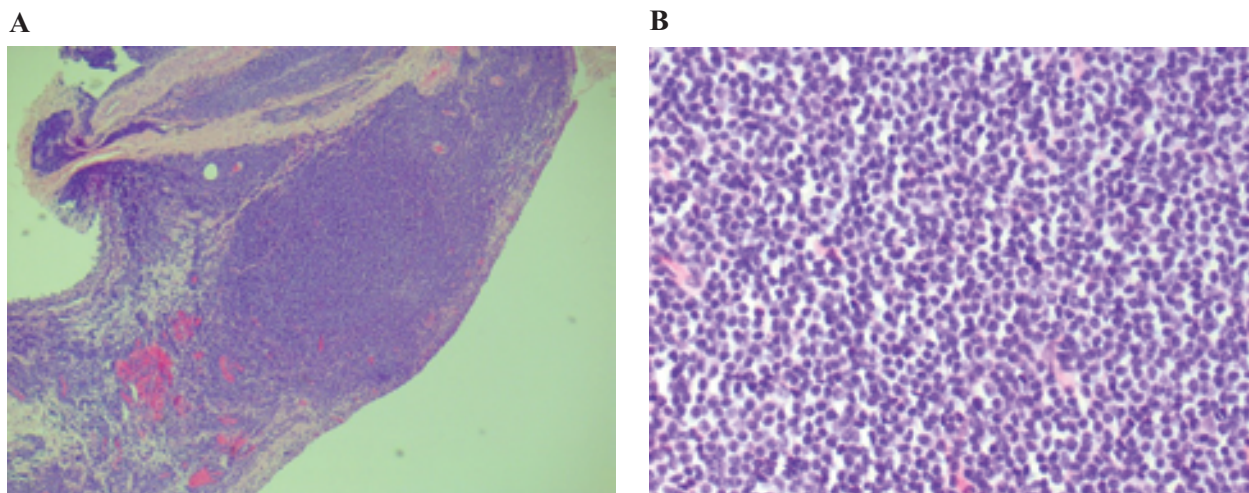


FIG. 2 (A) Microphotograph of urinary bladder biopsy showing dense sub-epithelial lymphocytic infiltrate (H and E, ×50). (B) Higher magnification of the same showing small lymphoid cells with coarsely clumped chromatin (H and E, ×400)



Hematology multidisciplinary team meeting decided on watchful waiting for his CLL. Continued surveillance of the bladder was decided as there is the possibility of progression to other bladder malignancies reported.⁶

DISCUSSION

Lymphoma of the bladder is a rare condition. The first ever reported case of bladder lymphoma was by Eve and Chaffey in 1885. There have been less than 100 cases described in the literature since. The disease typically presents in the sixth decade of life predominantly affecting women. Since lymphoid tissue is not found in the bladder, chronic inflammation is considered as an origin. The most common symptoms are weight loss, fatigue, dysuria, nocturia, urinary frequency, supra-pubic pain.⁷ There are different treatment options including observation, surgery including complete excision or biopsy, radiation chemotherapy, targeted antibody therapy. Lymphoma of the urinary bladder is a slow-growing malignancy with a generally good prognosis with early diagnosis and treatment.

Initial presentation of CLL with non-visible hematuria and storage LUTs is very rare. Cystoscopy is mandatory for evaluation. Further cystoscopic surveillance is advised because of malignant transformation.

CONFLICT OF INTEREST

Authors have no conflict of interest.

REFERENCES

1. Desai V, et al. Chronic lymphocytic leukemia of the bladder: an atypical etiology of gross hematuria. *Ther Adv Urol* 2014 Oct;6(5):198–200.
2. Cancer Research UK. Available at: <http://www.cancerresearchuk.org/about-cancer/type/cll/about/chronic-lymphocytic-leukaemia-risks-and-causes>
3. Lishner M, Prokocimer M, Ron E, Shaklai M. Primary malignant neoplasms associated with chronic lymphocytic leukemia. *Postgrad Med J* 1987;63:253–56 [PubMed].
4. Tsimberidou AM, Wen S, McLaughlin P, et al. Other malignancies in chronic lymphocytic leukemia/small lymphocytic lymphoma. *J Clin Oncol* 2009;27(6):904–10.
5. National Health Service. NHS Hematuria Pathways. Available at: <http://www.ouh.nhs.uk/services/referrals/renal/documents/hematuria-pathways.pdf>
6. Baseskiogulu B, et al. The type of lymphocyte infiltration near urothelial carcinoma is diagnostic for chronic lymphocytic leukemia. *Urol Ann* 2013 Jan;5(1):47–9
7. Prashant V, et al. Malt Lymphoma of the Bladder: A Case Report and Review of Literature. *Case Rep Haematol* 2015;(934374).